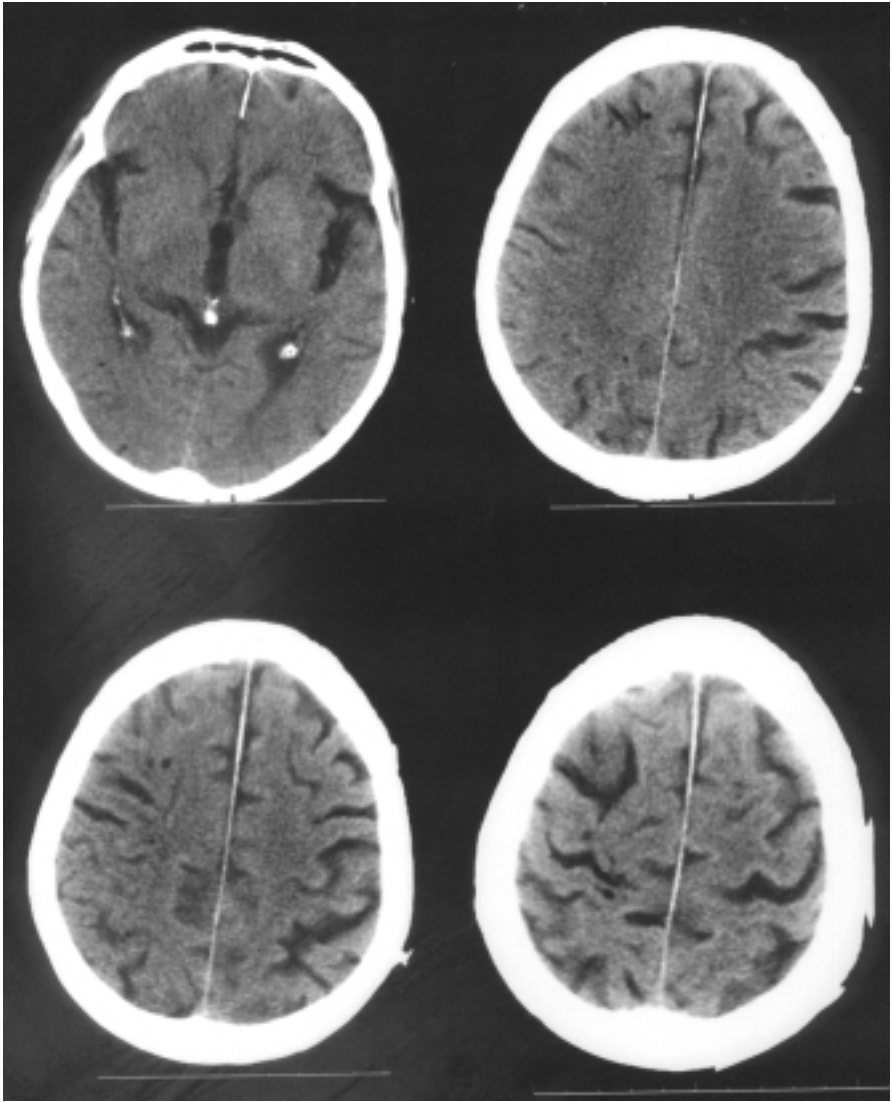Figure 4. CT Scan—Air Emboli