Figure 6. SVT with Concomitant Right Ventricular Hypertrophy

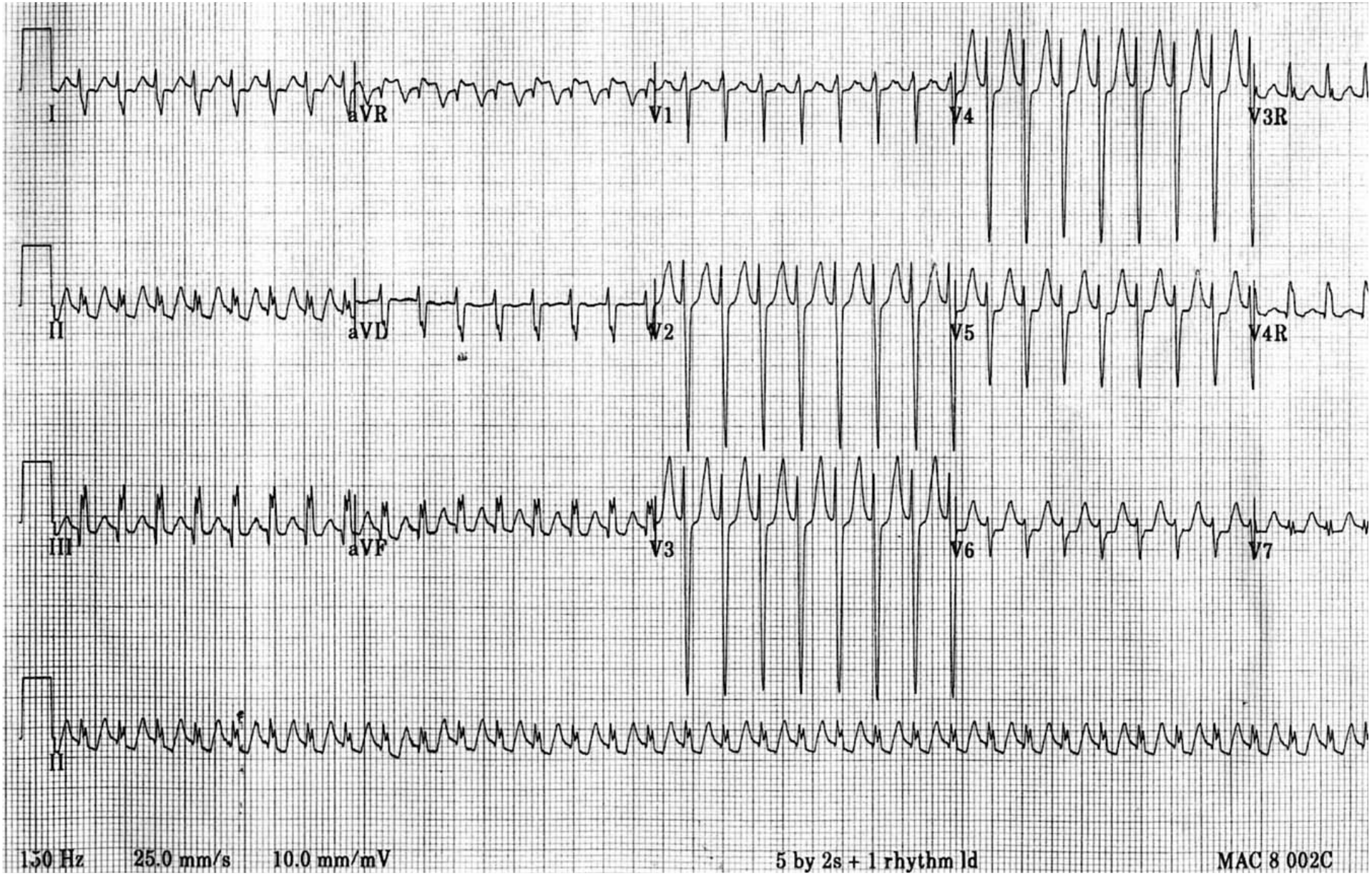

Figure 6. SVT with concomitant right ventricular hypertrophy. This 4-year-old male was post-operative from repair of congenital heart disease (Fontan repair). He was eventually converted to normal sinus rhythm after multiple doses of adenosine.

Courtesy of Stephanie Doniger, MD, Children's Hospital, San Diego, CA